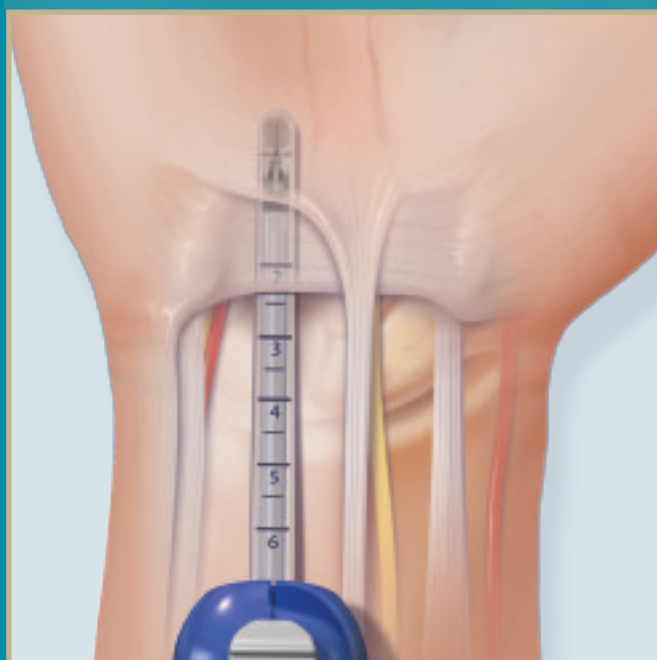




Centerline™ Endoscopic Carpal Tunnel Release

Surgical Technique

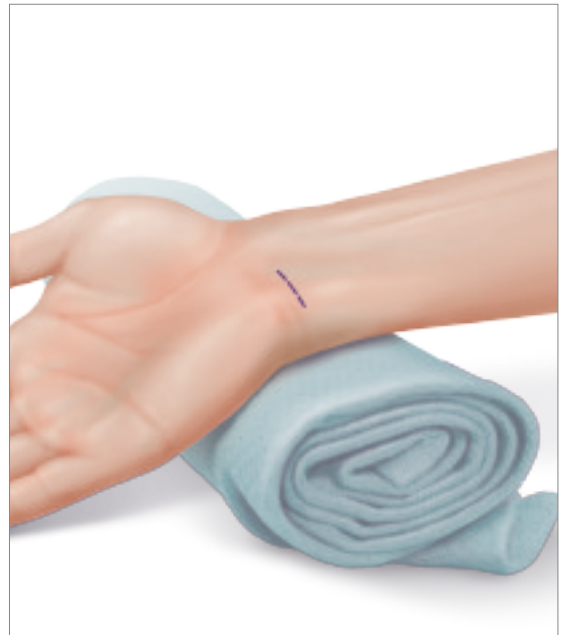

Centerline Carpal Tunnel Release

Centerline™ Endoscopic Carpal Tunnel Release

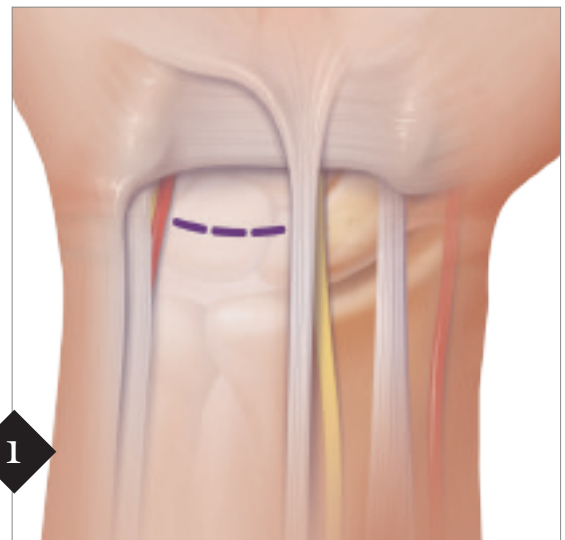
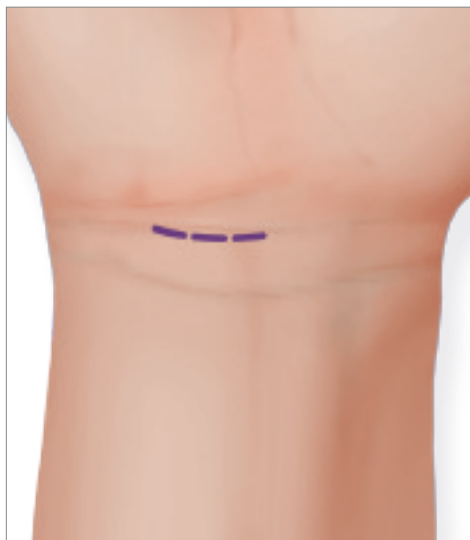
Surgical Set Up

The patient is positioned supine on the operating room table with the arm abducted on a hand table. It is useful to place the hand palm up in a holder or over a surgical towel so that the wrist is extended 15 – 20°. The hand, wrist, forearm and the arm proximal to the elbow should be completely exsanguinated using an Esmark bandage. The tourniquet is then elevated. The surgeon's hand, when holding the instrument, should naturally align the blade assembly so that it points axially from the ulnar side of the carpal tunnel to the base of the ring finger. This course is anatomically optimal for avoiding injury to the median nerve. Surgeons favoring right-handed use will usually prefer a position in the axilla for a right carpal tunnel release and cephalic position for a left release. It is vice versa for left-handed surgeons. The surgeon should be able to easily view the monitor over the assistant's right or left shoulder.

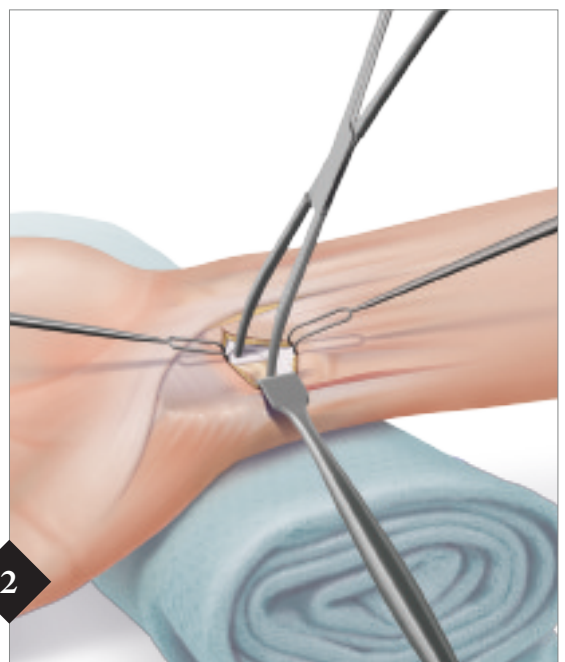


Operative Technique

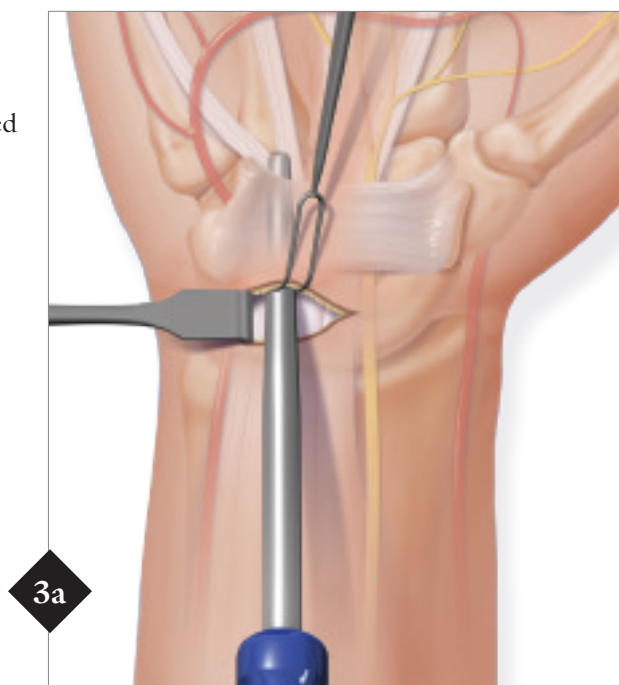
The surgical incision is placed transversely in one of the wrist flexion creases (usually the proximal) between the flexor carpi ulnaris and the palmaris longus. If the patient does not have a PL, the radial extent of the incision should be 2 cm ulnar to the flexor carpi radialis. The incision is usually 2 – 3 cm in length. Veins that cross the incision are coagulated with a bipolar and divided.



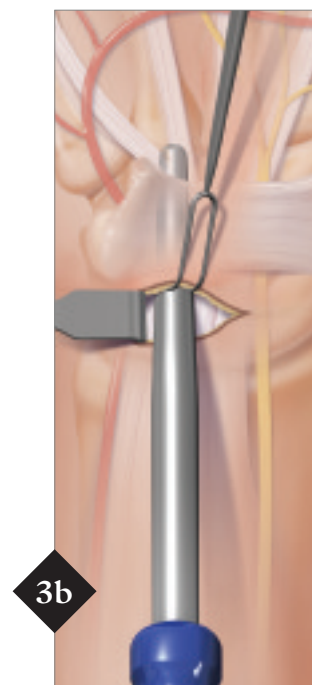
The soft tissue dissection is started on the radial aspect of the incision and taken directly down to the antebrachial fascia. This dissection is then swept in an ulnar direction. This method reveals a consistent plane that mobilizes Guyon's canal contents, allowing for their retraction out of harm's way. During this portion of the procedure, fascial bands are often encountered that may inhibit the mobilization of these tissues. This is overcome by simply dividing the restricting fascial bands. Once mobilized the subcutaneous fat and Guyon's canal contents are retracted in an ulnar direction with a blunt retractor. The antebrachial fascia is divided in line with the incision by simply spreading with a blunt tip scissor. This maneuver creates access to the carpal tunnel. A small two-prong skin retractor is placed on the leading edge of the transverse carpal ligament and used to elevate this structure.



The Centerline™ instrumentation is equipped with two sequential sized Hagar Dilators that are used to dilate the carpal tunnel and create a track for the Centerline. Aim the Dilators at the base of the ring finger while holding the wrist in slight extension. Gently pass the Dilators distally down the ulnar side of the tunnel hugging the hook of the hamate, and advancing distally until the tip is past the carpal tunnel.

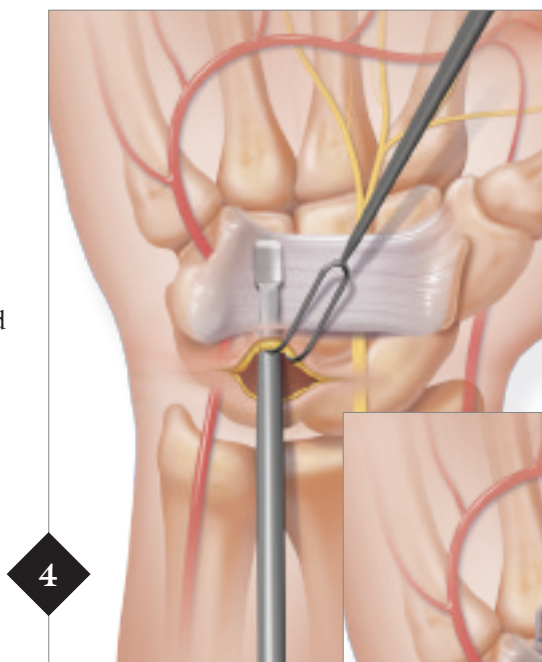


4.8 mm Dilator



6.8 mm Dilator

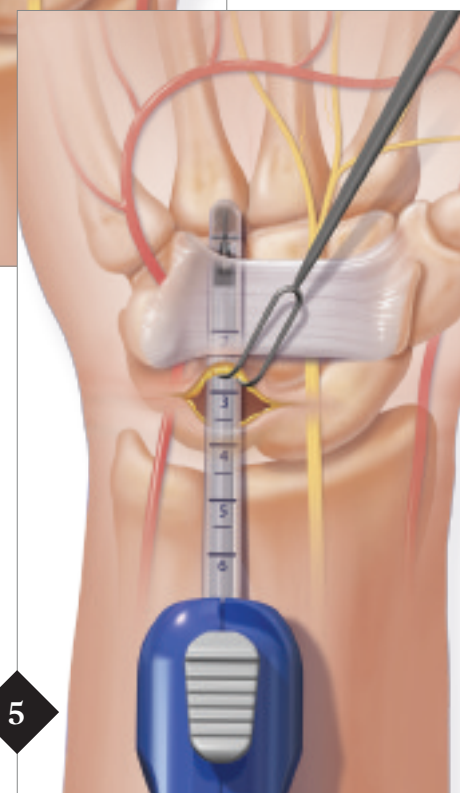
A small Synovial Elevator is used to dissect adherent synovium from the underside of the transverse carpal ligament. This is a critical step because the safety of this procedure is directly related to clear visualization of the underside of the transverse carpal ligament. Follow the same path as the Dilators and scrape the underside of the transverse carpal ligament. A noticeable rough, washboard like effect will be felt. The carpal tunnel is now prepared for insertion of the Centerline device, however, it is important to check blade extension and retraction before insertion into the patient's hand.



4

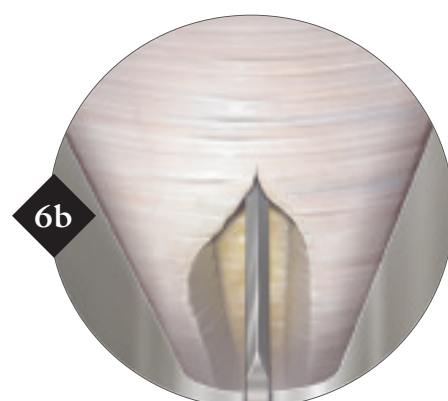
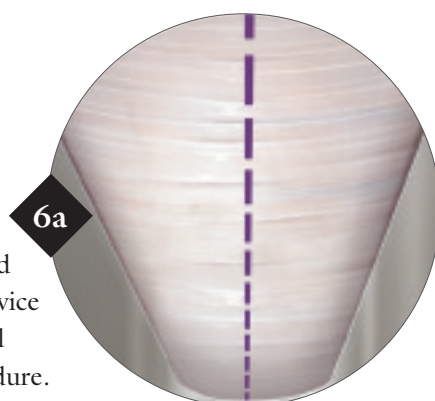
With the patient's wrist in slight extension, insert the Centerline into the carpal tunnel, pressing the viewing window snugly against the deep side of the ligament. While aiming at the base of the ring finger, advance the instrument distally, hugging the hook of the hamate to assure an ulnar course. Use a sufficient number of proximal-to-distal passes to accurately define an ulnar "strip" of the transverse carpal ligament. Transverse fibers of the ligament should be visible within this strip. Palpating with the thumb, define the distal margin of the ligament at its junction with a pad of fat and align the point of entry markers at this junction.

Caution: The fat typically overlaps the deep side of the ligament's distal margin by a couple of millimeters.³ This contrasts with the occasional patient that lacks a clear distal margin of this ligament as defined by its junction with a pad of fat. If this or other anatomic details fail to provide orientation to critical anatomy, abandon the endoscopic approach in favor of an open carpal tunnel release.

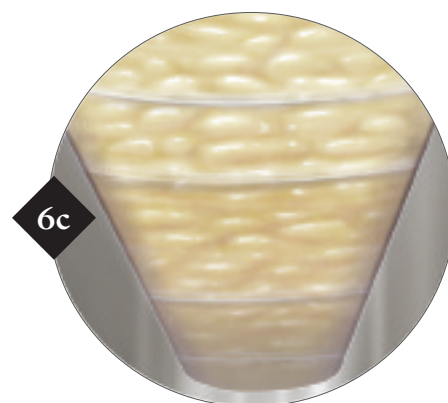


5

Once a clear path from the distal end of the transverse carpal ligament (TCL) to the proximal end is confirmed, the knife is deployed distally and the transverse carpal ligament is divided as the device is withdrawn along the previously established path. It is important to ensure that the device hugs the underside of the transverse carpal ligament during this portion of the procedure.



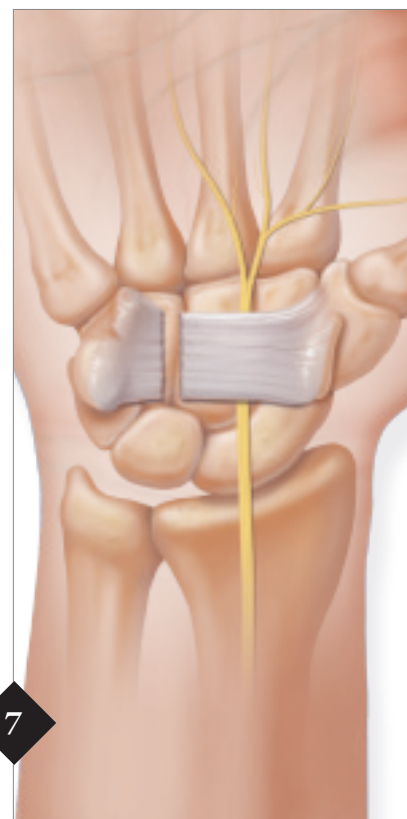
The device is reinserted to confirm complete division of the transverse carpal ligament. It should be easier to insert the device after TCL division. The spread of the TCL will often reveal a few distal fibers that are divided at this time taking care not to deploy the knife into the fat pad which can cause injury to the superficial palmar arch. The Centerline™ may be rotated (blade retracted) after a complete release to allow the surgeon to inspect the cut edges of the ligament.



In addition to the video monitor image, assess completeness of ligament division by several means; sensing the reduced “pressure” upon the instrument when it is reinserted in a decompressed carpal tunnel; noting the more subcutaneous course of the blade assembly after division; the scope light shining through the skin without obstruction; inserting a small right-angle retractor and looking directly inside of the released carpal tunnel at the cut edges of the ligament. In a few cases there will be a persistent constriction of the proximal forearm fascia on carpal tunnel contents. In these cases, it may be necessary to release the proximal forearm fascia. Using tenotomy scissors, release the forearm fascia proximal to the skin incision, taking care to protect the median nerve. This prevents the forearm fascia from acting as a constricting band that could continue to compromise median nerve function.

The wound is closed with a subcuticular suture which yields the best cosmetic results. It is a good idea to inject marcaine without epinephrine into the carpal tunnel for immediate postoperative pain control. The wound is dressed with zeroform, gauze sponge and Coban and the tourniquet is released. The Coban bandage is changed to a BAND-AID® before the patient leaves the postoperative holding area.

Aftercare: The wound is kept clean and dry for 10 – 14 days. Activity is only restricted by the patient’s comfort level as there are no mandatory restrictions.* The wound is checked at two weeks postoperative and a final check is performed at six weeks postoperative.



References

* Post op procedure described by Steven Topper, MD

1. Agee, JM et al. *Endoscopic Release of the Carpal Tunnel A Randomized Prospective Multicenter Study*, Journal of Hand Surgery, 1992, 17(6)987-995.
2. Agee, JM et al. *Endoscopic Carpal Tunnel Release A Prospective Study of Complications and Surgical Experience*, Journal of Hand Surgery, 1995, 20A(2)165-171.
3. Rotman, MB, Manske, PR. *Anatomic Relationships of an Endoscopic Carpal Tunnel Device to Surrounding Structures*, Journal of Hand Surgery, 1993, 18A(3)442-450.

Ordering Information

Centerline ECTR	AR-8850
Centerline ECTR Instrument Set	AR-8850S
Centerline Scope	AR-3350-2930

See back panel for complete ordering details

Indication

The Centerline™ Carpal Tunnel Release System is indicated for patients diagnosed with carpal tunnel syndrome.

Contraindication

Patients with known abnormalities of the wrist affecting the carpal tunnel, including distal radius and wrist deformities, rheumatoid, or other diseases of the synovium, have not been studied and are contraindicated. Patients with congenital anatomical abnormalities, particularly those with abnormalities of the hook of the hamate, and patients with smaller hands or an unusually tight carpal tunnel are also contraindicated. Do not use for surgeries other than those indicated.

Introduction

Traditionally, a patient treated surgically for carpal tunnel syndrome could expect significant recovery time away from work due to the surgical wound in the palm and heel of the hand. When the carpal tunnel is released endoscopically clinical results indicate that postoperative morbidity is improved and time away from normal activities and full employment are reduced by as much as 46%.¹ The safety of endoscopic carpal tunnel release has been documented in a large clinical series involving over 1,000 cases in a 63 multicenter study.² The results of this study showed minimal complications. The Centerline incorporates improved safety features compared to other ECTR devices that have been used for over 20 years. The Centerline concept eliminates rotational moments and offers superior visualization. The thumb trigger pull is synergistic—increasing steadiness and facilitating control. The integrated disposable unit significantly diminishes the risk of mechanical failure and part loss or damage. The Centerline Carpal Tunnel Release System attaches to any standard video camera and light source. The surgeon introduces the device into the carpal tunnel through a limited incision in the wrist flexor crease. Viewing the deep side of the transverse carpal ligament (flexor retinaculum) under direct visualization at the tip of the instrument, the surgeon elevates the blade to cut the ligament as the instrument is withdrawn.

The Centerline Carpal Tunnel Release System uses a dry procedure. No fluid or gas should be introduced into the carpal tunnel during this procedure. A general or regional anesthetic is strongly recommended. Local anesthesia or Bier block are ill-advised due to fluid potentially obscuring visualization.

This device and surgical procedure was developed in conjunction with Steven Topper, MD, of the Colorado Hand Center.

Ordering Information



Centerline™ Disposable Device

Centerline ECTR	AR-8850
<i>Scope sold separately</i>	

Centerline Scope

Reverse Post Light Scope, 2.9 mm	AR-3350-2930
----------------------------------	--------------

Centerline Instrument Set (AR-8850S) includes:

Dilator, 4.8 mm	AR-8851
Dilator, 6.8 mm	AR-8852
Synovial Elevator	AR-8853
Instrument Case for Scope	AR-8850SC
Centerline ECTR Instrument Case	AR-8850DC

This description of technique is provided as an educational tool and clinical aid to assist properly licensed medical professionals in the usage of specific Arthrex products. As part of this professional usage, the medical professional must use their professional judgment in making any final determinations in product usage and technique. In doing so, the medical professional should rely on their own training and experience and should conduct a thorough review of pertinent medical literature and the product's Directions For Use.



View U.S. patent information at www.arthrex.com/corporate/virtual-patent-marking

© 2015, Arthrex Inc. All rights reserved. LT1-0412-EN_C