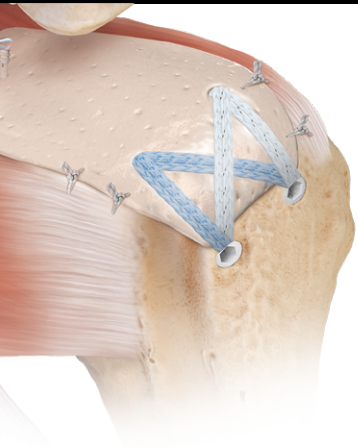


Superior Capsular Reconstruction Scientific Update



Nimura A,
Kato A,
Yamaguchi K,
Mochizuki T,
Okawa A,
Sugaya H,
Akita K

Superior Capsular Reconstruction (SCR) has emerged as a viable technique for isolated treatment of rotator cuff tears and in conjunction with rotator cuff repair for cases with poor healing potential. Anatomically, SCR has a strong foundation because the superior capsule typically provides a static, superior restraint. Biomechanically, massive rotator cuff tears lead to increased superior migration of the humeral head, which can be restored with SCR. Clinically, SCR has demonstrated improved functional outcomes. SCR has evolved and is dependent on precise graft measurement and strong fixation.

Anatomical Studies

[The superior capsule of the shoulder joint complements the insertion of the rotator cuff.](#) *J Shoulder Elbow Surg.* 2012;21(7):867-872. doi:10.1016/j.jse.2011.04.034

- This anatomic study of the superior capsule and rotator cuff insertion, in contrast to previous studies, viewed the capsule and rotator cuff insertions as a unit; the capsule and rotator cuff were dissected separately to determine the insertion of each on the shoulder joint
- The superior capsule occupied 3.5 mm (minimum) to 9.1 mm (maximum) of the insertion on the greater tuberosity
- At the anterior and posterior margins of the greater tuberosity, the superior capsule occupied a greater footprint than the rotator cuff

Takeaway

- **The superior capsule is an important anatomic structure that occupies a substantial amount of the insertion on the greater tuberosity. Therefore, the superior capsule should be considered during rotator cuff repair; this also provides an anatomic basis for SCR when the rotator cuff cannot be repaired.**

Biomechanical Studies

[Superior capsule reconstruction to restore superior stability in irreparable rotator cuff tears: a biomechanical cadaveric study.](#) *Am J Sports Med.* 2012;40(10):2248-2255. doi:10.1177/0363546512456195

- Massive rotator cuff tears were simulated in 8 cadavers, followed by patch graft vs SCR
 - Patch grafts were sewn to remaining cuff medially
 - SCR graft was secured to glenoid medially
 - Both grafts were secured to the greater tuberosity
- Superior translation and subacromial pressure increased following a rotator cuff tear
- Subacromial pressure was restored after both procedures
- Only SCR restored superior translation

Takeaway

- **Superior capsule reconstruction with medial fixation to the glenoid, as opposed to sewing into the remaining rotator cuff medially (patch grafting), results in restoration of superior translation in a massive rotator cuff model. A patch graft does not restore superior translation to baseline levels.**

Mihata T,
McGarry MH,
Pirolo JM,
Kinoshita M,
Lee TQ



Mihata T,
McGarry MH,
Kahn T,
Goldberg I,
Neo M,
Lee TQ

[Biomechanical role of capsular continuity in superior capsule reconstruction for irreparable tears of the supraspinatus tendon.](#) *Am J Sports Med.* 2016;44(6):1423-1430. doi:10.1177/0363546516631751

- SCR was tested in 7 cadavers, comparing SCR alone to the addition of 1) posterior margin convergence to the native rotator cuff and 2) anterior and posterior margin convergence
- SCR without margin convergence decreased subacromial contact pressure, but did not reduce superior translation
- The addition of posterior margin convergence suturing reduced superior translation
- Anterior margin convergence did not provide any benefit

Takeaway

- **Posterior margin convergence to the native rotator cuff is essential during SCR.**

Mihata T,
Bui CNH,
Akeda M,
Cavagnaro MA,
Kuenzler M,
Peterson AB,
McGarry MH,
Itami Y,
Limpisvasti O,
Masashi N,
Lee TQ

[A biomechanical cadaveric study comparing superior capsule reconstruction using fascia lata allograft with human dermal allograft for irreparable rotator cuff tear.](#) *J Shoulder Elbow Surg.* 2017;26(12):2158-2166. doi:10.1016/j.jse.2017.07.019

- 8 cadavers were used to compare SCR with fascia lata (FL) and humeral dermal (HD) allografts
- Superior humeral translation was approximately 2 mm in the intact state and increased to approximately 8 mm following a simulated rotator cuff tear
- Following SCR with HD allograft, superior translation was reduced by 50% to approximately 4 mm. This was statistically significant compared to the tear state at 0° and 30° of abduction.
- Following SCR with FL, superior translation was reduced to approximately 1 mm
- HD allografts elongated approximately 15% during testing

Takeaway

- **Both FL and HD allografts decreased superior translation in a rotator cuff tear model. HD allograft does not decrease superior translation to native levels. However, FL provided a supraphysiologic reduction in translation, which may also have clinical consequences (ie, excessive restraint leading to arthritis). HD allograft is elastic and therefore elongates during testing. This should be considered during tensioning, as well as during suture placement (ie, consider securing HD allograft at slightly higher degrees of abduction or place sutures 10%-15% inside of measured dimensions).**

Pogorzelski J,
Muckenhirn KJ,
Mitchell JJ,
Kattagen JC,
Schon JM,
Dahl KD,
Hirahara AM,
Dines JS,
Adams CR,
Dooney T,
Denard, P,
Turnbull TL,
Millett PJ

[Biomechanical comparison of 3 glenoid-side fixation techniques for superior capsular reconstruction.](#) *Am J Sports Med.* 2018;46(4):801-808. doi:10.1177/0363546517745626

- 36 cadavers were randomized to test glenoid-sided fixation of the dermal allograft
 - 3 knotless screw-in anchors (3.5 mm SwiveLock® anchor) with central labral tape and cinch sutures on the corners
 - 3 knotless push-in anchors (3.0 mm Knotless SutureTak® anchor) with independent mattress sutures
 - 4 anchors in a hybrid construct, using a central double-pulley (two 3.0 standard SutureTak anchor) and peripheral cinch sutures (two 2.9 mm PushLock® anchor)
- There was no difference in load-to-failure between techniques 1 and 2
- Fixation strength was highest with independent fixation (techniques 1 and 2)

Takeaway

- **Independent glenoid fixation with 3 knotless anchors provides the strongest construction for glenoid-sided fixation of SCR.**



Pashuck TD,
Hirahara AM,
Cook JL,
Cook CR,
Andersen WJ,
Smith MJ

Clinical Studies

Superior capsular reconstruction using dermal allograft is a safe and effective treatment for massive irreparable rotator cuff tears: 2-year clinical outcomes [published online October 17, 2020]. *Arthroscopy*. 2020;S0749-8063(20)30844-6. doi:10.1016/j.arthro.2020.10.014

- Retrospective multicenter evaluation of 14 SCRs performed with dermal allograft and reviewed 2 years postoperative
 - Excluded cases with Hamada 4 or 5 and substantial (3 of 5) external rotation weakness
 - MRI and ultrasound evaluations were performed at 6 and 12 months post-op
 - Grafts were secured with the arm in neutral abduction and rotation
 - A medial double-pulley was used to secure the graft to the glenoid
- ASES scores improved from 55 preoperatively to 87 at 2 years postoperatively ($P < .001$)
- Graft status
 - MRI: 8/12 (67%) intact at 1 year
 - Ultrasound: 8/12 (67%) had documented vascularity at 1 year with a mean graft thickness of 4.3 mm
 - All graft failures occurred at the glenoid

Takeaways

- **SCR with the dermal allograft secured with the arm in neutral abduction and rotation results in improved functional outcomes at 2 years postoperatively and an encouraging rate of graft integrity at 1 year postoperatively.**
- **Dermal allograft is capable of vascularization as evidenced by vascular flow on postoperative ultrasound.**
- **More recent techniques have encouraged independent medial glenoid fixation. Such a technique may improve upon the medial failures (using a double-pulley technique) observed in this study.**

Mihata T,
Lee TQ,
Watanabe C,
Fukunishi K,
Ohue M,
Tsujimara T,
Kinoshita M

Clinical results of arthroscopic superior capsule reconstruction for irreparable rotator cuff tears. *Arthroscopy*. 2013;29(3):459-470. doi:10.1016/j.arthro.2012.10.022

- Retrospective evaluation of 24 SCRs using FL for irreparable rotator cuff tears reviewed at a minimum of 2-years postoperative
- Acromiohumeral distance increased from 4.6 mm preoperatively to 8.7 mm postoperatively
- ASES scores improved from 24 preoperatively to 93 postoperatively
- 83% of the grafts healed

Takeaway

- **This was the first clinical study that demonstrated the clinical utility of SCR in the treatment of irreparable rotator cuff tears with substantial improvements in all clinical parameters.**



Denard PJ,
Brady PC,
Adams CR,
Tokish JM,
Burkhart SS

[Preliminary results of arthroscopic superior capsule reconstruction with dermal allograft.](#)
Arthroscopy. 2018;34(1):93-99. doi:10.1016/j.arthro.2017.08.265

- Retrospective review of SCR with dermal allograft
- 59 patients were evaluated 1 year after SCR with dermal allograft using earlier techniques (2 medial anchors and knotless fixation on the tuberosity)
- Successful outcomes were achieved in 68% of cases
 - 76% success rate in Hamada 1 and 2 cases
 - 44% success rate in Hamada 3 and 4 cases
- 100% of grafts that healed were considered clinical successes based on postoperative function

Takeaways

- **The results of this study should be considered as an initial series with broad indications and a high percentage of cases were for revision (42%). It should also be noted that the technique has evolved substantially since this original publication.**
- **When graft healing occurred, functional outcome was excellent. This highlights the importance of strong fixation and slow rehabilitation.**
- **The outcome varied by indication and the best results were in patients without arthritis (Hamada 1 and 2). Patients with adaptive changes of the proximal humerus or arthritis were less likely to see improvement.**

Pennington WT,
Bartz BA,
Pauli JM,
Walker CE,
Schmidt W

[Arthroscopic superior capsular reconstruction with acellular dermal allograft for the treatment of massive irreparable rotator cuff tears: short-term clinical outcomes and the radiographic parameter of superior capsular distance.](#) *Arthroscopy.* 2018;34(6):1764-1773. doi:10.1016/j.arthro.2018.01.009

- Retrospective review at a minimum 1-year postoperative of 86 patients who underwent SCR with dermal allograft
- No patients had severe arthritis or adaptive changes
- ASES scores improved from 52 to 82
- Acromiohumeral distance increased from 7.1 mm to 9.7 mm

Takeaway

- **In properly selected patients (absence of arthritis or adaptive changes), SCR with dermal allograft leads to reduction in pain and improvement in functional outcomes.**



Burkhart SS,
Hartzler RU

[Superior capsular reconstruction reverses profound pseudoparalysis in patients with irreparable rotator cuff tears and minimal or no glenohumeral arthritis.](#) *Arthroscopy*. 2019;35(1):22-28. doi:10.1016/j.arthro.2018.07.023

- SCR with dermal allograft was used to treat 10 patients with profound pseudoparalysis (defined as forward flexion of <45°)
- 9 out of 10 patients recovered overhead elevation
- 70% of grafts were fully intact on MRI and 30% were partially intact

Takeaway

- **SCR can be used for joint preservation, even in the setting of pseudoparalysis.**

Mihata T,
Lee TQ,
Hasegawa A,
Fukunishi K,
Kawakami T,
Fujisawa Y,
Ohue M,
Doi M,
Neo M

[Superior capsule reconstruction for reinforcement of arthroscopic rotator cuff repair improves cuff integrity.](#) *Am J Sports Med*. 2019;47(2):379-388. doi:10.1177/0363546518816689

- 34 SCRs with combined rotator cuff repair were compared to 91 isolated rotator cuff repairs
- Mean follow-up was 36 months (range 24-52 months)
- SCR was combined with rotator cuff repair, even if the cuff could be repaired alone, if the rotator cuff demonstrated poor potential for healing
 - Poor healing was determined as 2 of 3 of significant atrophy, tendon degeneration, or tendon retraction medial to the humeral head
- Despite the association of these factors with poor healing, there were no retears in the patients with combined SCR and cuff repair

Takeaway

- **SCR may have an important role not only in the treatment of irreparable rotator cuff tears, but also as an anatomic augmentation in patients with poor healing potential due to advanced atrophy and tendon degeneration.**

Mihata T,
Lee TQ,
Hasegawa A,
Fukunishi K,
Kawakami T,
Fujisawa Y,
Ohue M,
Neo M

[Five-year follow-up of arthroscopic superior capsule reconstruction for irreparable rotator cuff tears.](#) *J Bone Joint Surg Am*. 2019;101(21):1921-1930. doi:10.2106/JBJS.19.00135

- Minimum 5-year follow-up of 30 patients who underwent SCR with FL graft
- Functional outcome was maintained compared to 1-year post-op and, in fact, ASES scores significantly improved from 1 year to 5 years postoperative
- 27 of 30 grafts healed
 - None of the grafts with healing developed arthritis
 - All 3 patients with failure of healing developed rotator cuff arthropathy by 5 years postoperative

Takeaway

- **5-year outcomes of the SCR appear to be durable. Moreover, a healed graft may interrupt the natural history of a massive rotator cuff tear by preventing rotator cuff arthropathy.**



Minimum 2-year clinical outcomes after superior capsule reconstruction compared with reverse total shoulder arthroplasty for the treatment of irreparable posterosuperior rotator cuff tears in patients younger than 70 years. *J Shoulder Elbow Surg.* 2020;29(12):2514-2522. doi:10.1016/j.jse.2020.04.002

- Retrospective comparative study of 2-year outcomes of irreparable rotator cuff tears in patients younger than 70 years of age who did not have glenohumeral osteoarthritis
 - 22 SCRs
 - 3 mm dermal allograft secured with 3 knotless glenoid anchors and lateral SpeedBridge™ repair
 - 29 rTSAs
 - 155 Grammont-style protheses
- Patients in the SCR group were slightly younger (57 years compared to 63 years; $P < .001$) but otherwise there was no difference in function at baseline
- Both groups improved significantly with no differences in ASES, SANE, or SF-12 scores
- Return to sports was 94% in the rTSA group and 100% in the SCR group

Takeaways

- **At 2 years postoperatively, both SCR and rTSA led to significant improvement in functional outcomes and a high rate of return to activity in patients younger than 70 years of age.**
- **Given longevity concerns with arthroplasty in young patients, joint preservation with SCR may be preferable to rTSA in young patients who have an irreparable rotator cuff tear but have not yet developed glenohumeral osteoarthritis.**